



PATIENT

Bella Romano

SPECIES

Canine

BREED

Cockapoo

SEX

Female Spayed

AGE

12 years

WEIGHT

26.5lbs

PRESENTING CLINICAL SIGNS

History: New grade II/VI systolic murmur. No clinical signs. Echocardiogram prior to anesthesia for dental prophy and mass removal.

ECHOCARDIOGRAM FINDINGS

2D, m-mode, color flow and Doppler imaging is available.

Left ventricle: The LV diameter is normal with adequate myocardial function. LV wall thicknesses are normal.

Left atrium: The left atrium is normal.

Mitral valve: The mitral valve is mildly thickened with no prolapse into the left atrial lumen. Trace central mitral regurgitation.

Aortic valve/aorta: The aortic valve is normal in morphology and mobility. Normal aortic outflow velocity; laminar flow. No aortic insufficiency.

Right ventricle: Normal right ventricular diameter and morphology indicating no overt evidence of pulmonary arterial hypertension.

Right atrium: Normal RA dimension.

Tricuspid valve: The tricuspid valve appears normal with trace tricuspid regurgitation; normal velocity.

Pulmonic valve/pulmonary artery: The pulmonic valve is normal in morphology and mobility. No pulmonic insufficiency. Normal RVOT velocity; laminar flow.

Pericardium/other: No pericardial or pleural effusion noted. No obvious cardiac masses.

2-Dimensional Measurements

Ao diam (cm)	1.8
LA diam (cm)	2.0
LA:Ao (Swe)	1.1
IVS thickness (cm)	0.9
LVID diastole (cm)	2.8
PW thickness (cm)	0.9
LVID systole (cm)	1.6
FS (%)	43

Doppler Measurements

PV Vmax (m/s)	0.86
AoV Vmax (m/s)	1.6
MR Vmax (m/s)	NM
TR Vmax (m/s)	2.2
TR PG (mmHg)	19

INTERPRETED BY

Maggie Machen
Lamy, DVM
DACVIM (Cardiology)

IMAGING

PERFORMED BY

Pamela Harrigan,
RDCS

HOSPITAL NAME

Wood River Animal
Hospital

REFERRING VET

Dr. Fischer

INTERPRETATION OF THE FINDINGS

The cause of the murmur is chronic degenerative valve disease causing trace leaks in the mitral and tricuspid valves. Lack of significant left atrial enlargement indicates the current risk for complication is low. It is unclear if these mild leaks would be heard on exam and other possibilities for the murmur should also be considered (i.e., such as a physiologic origin). No concurrent issues such as systolic dysfunction or pulmonary hypertension are noted in this study.

Assessment of progression in the future will help predict long term prognosis, which is highly variable at this stage (B1).

INVOICE

23953

DATE

4/29/22

RECOMMENDATIONS

- In a dog without significant left atrial enlargement, no cardiac medications are clearly indicated.
- Omega fatty acid supplementation and mild salt restriction may be of some long-term benefit.



PATIENT

Bella Romano

- No cardiac contraindication for general anesthesia prior to chamber enlargement.
- Monitor for development of a cough, labored breathing, exercise intolerance or collapse episodes.

SPECIES

Canine

PLAN

- Recommend conservative monitoring with a recheck echocardiogram in 6-12 months, sooner if any development of clinical signs.

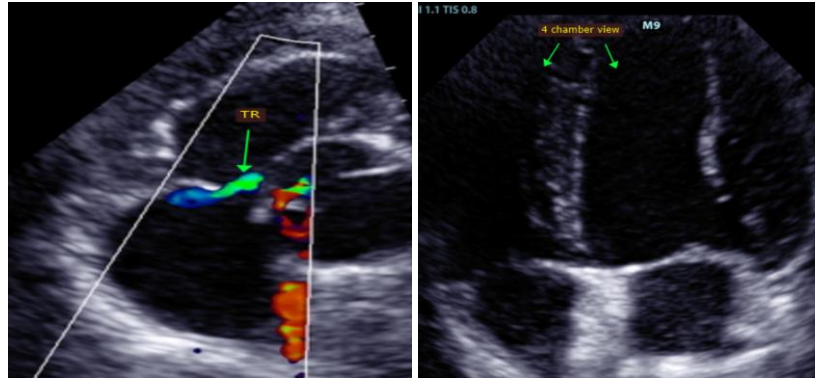
BREED

Cockapoo

IMAGES

SEX

Female Spayed



AGE

12 years

WEIGHT

26.5lbs

The information and recommendations provided are based on the images presented by the referring veterinarian. No evaluation can be communicated regarding pathology that was not visible in the image/video clips provided.

INTERPRETED BY

Maggie Machen
 Lamy, DVM
 DACVIM (Cardiology)

Thank you for this referral. This report was generated using transcription software, and minor dictation errors may be present. If the clinical or image interpretation does not parallel your findings or if I can be of any further assistance, please contact me.

IMAGING PERFORMED BY

Pamela Harrigan,
 RDCS

Maggie Machen Lamy, DVM
 Diplomate of the American College of Veterinary Internal Medicine (Cardiology)
 info@sonopath.com

HOSPITAL NAME

Wood River Animal
 Hospital

REFERRING VET

Dr. Fischer

INVOICE

23953

DATE

4/29/22